Clinical cases CrystalCam

A comparison of SPECT/CT (and standard gamma camera) and CrystalCam

Melanoma

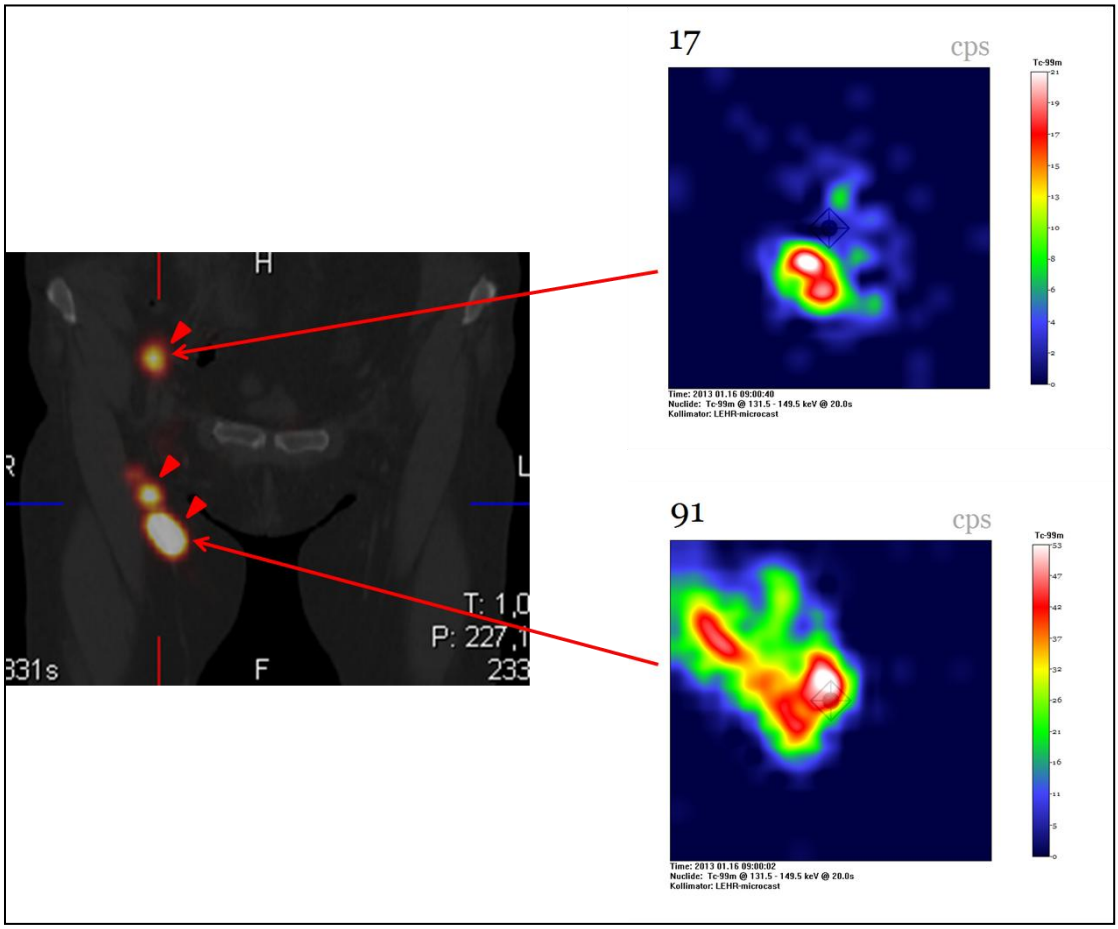

Images courtesy of University Hospital Leipzig, Department of Nuclear Medicine. Director and Chairman: Prof. Dr. Osama Sabri, MD, PhD

Left: SPECT/CT of a woman with melanoma. Image acquired with typical SPECT/CT acquisition times (15 – 20 sec. per angular increment).

Right: Images acquired pre-operatively by CrystalCam. 20 sec. acquisition times each with high resolution collimator. Upper image shows 1 lymph node. Bottom image shows 3 lymph nodes.

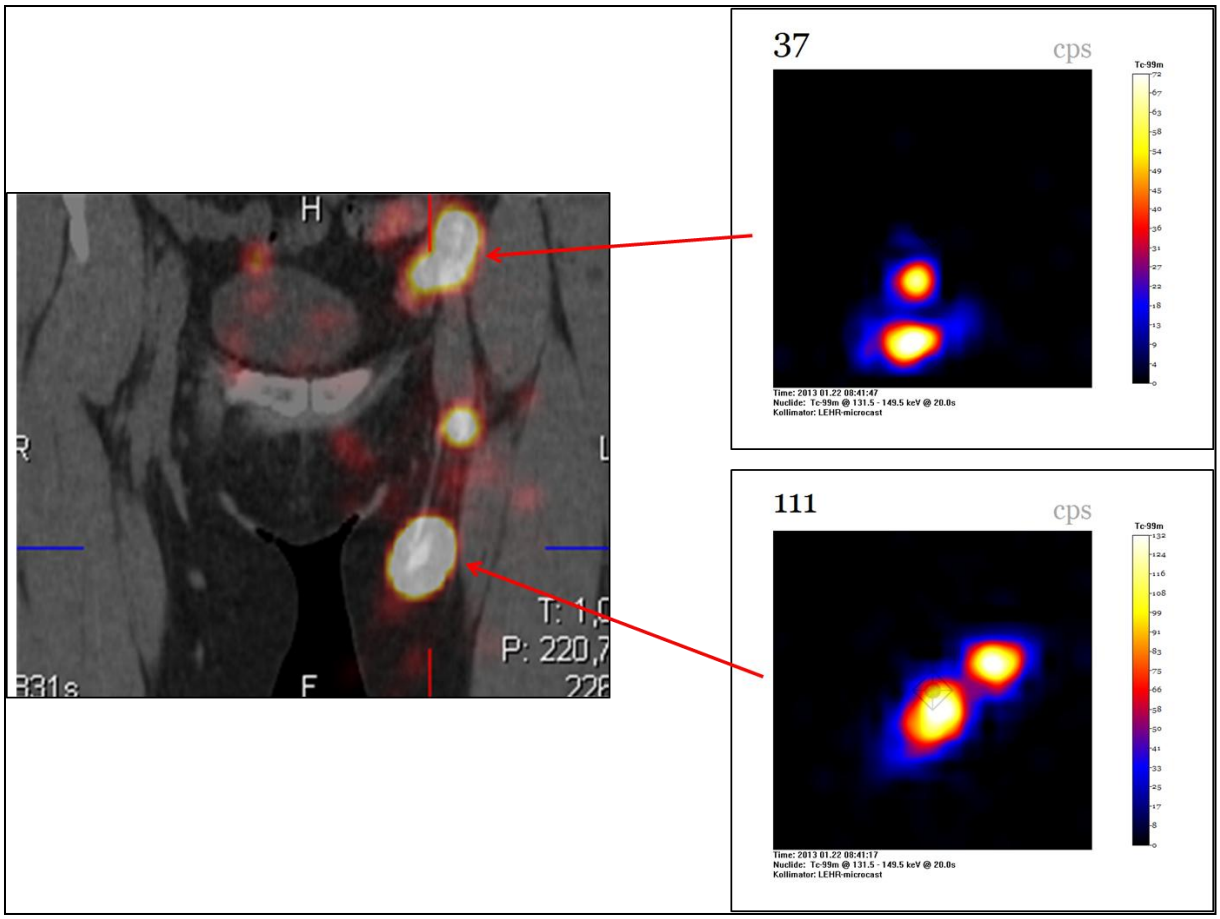

Images courtesy of University Hospital Leipzig, Department of Nuclear Medicine. Director and Chairman: Prof. Dr. Osama Sabri, MD, PhD

Left: SPECT/CT of a woman with melanoma. Image acquired with typical SPECT/CT acquisition times (15 – 20 sec. per angular increment).

Right: Images acquired pre-operatively by CrystalCam. 20 sec. acquisition times each with high resolution collimator. Upper image shows 2 lymph nodes. Bottom image shows 2 lymph nodes.

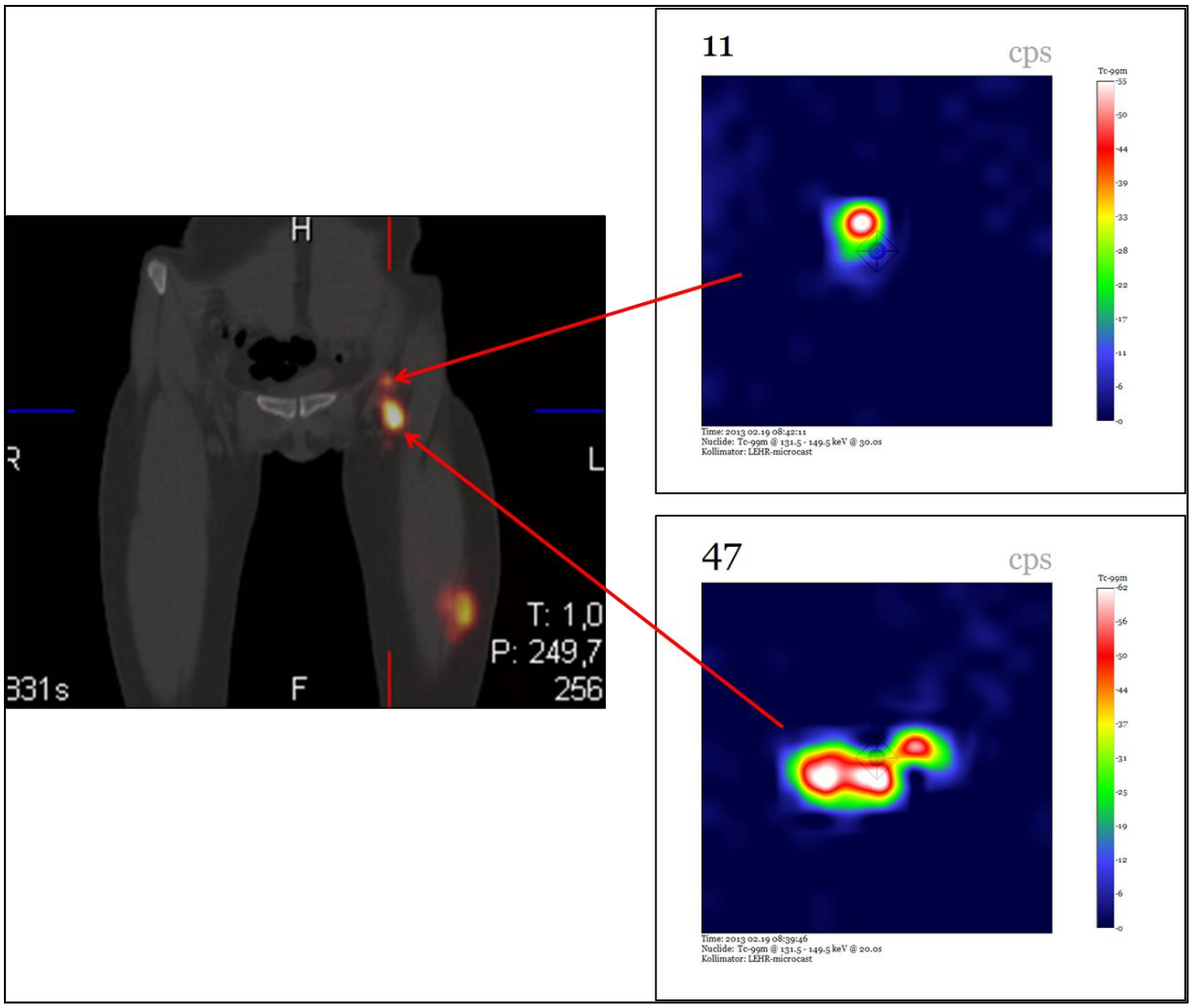

Images courtesy of University Hospital Leipzig, Department of Nuclear Medicine. Director and Chairman: Prof. Dr. Osama Sabri, MD, PhD

Left: SPECT/CT of a woman with melanoma. Image acquired with typical SPECT/CT acquisition times (15 – 20 sec. per angular increment).

Right: Images acquired pre-operatively by CrystalCam with high resolution collimator.
Upper image shows 1 lymph node (30 sec. acquisition time).
Bottom image shows 2 lymph nodes (20 sec. acquisition time).

Head and Neck Cancer

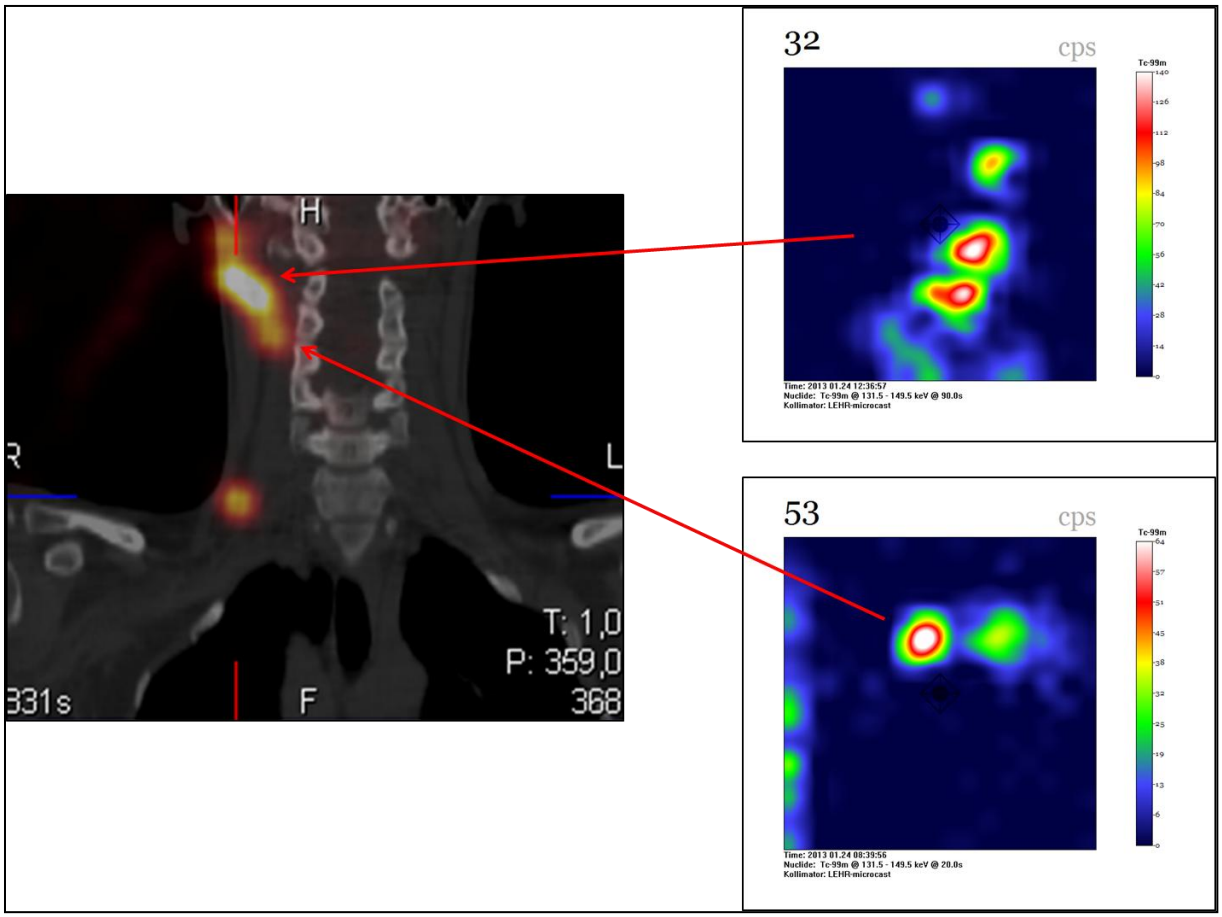

Images courtesy of University Hospital Leipzig, Department of Nuclear Medicine. Director and Chairman: Prof. Dr. Osama Sabri, MD, PhD

Left: SPECT/CT of a person with head and neck cancer. Image acquired with typical SPECT/CT acquisition times (15 – 20 sec. per angular increment).

Right: Images acquired by CrystalCam with high resolution collimator.
Upper image shows 3 lymph nodes acquired intra-operatively with 90 sec. acquisition time.
Bottom image shows 2 lymph nodes pre-operatively with 20 sec. acquisition time.

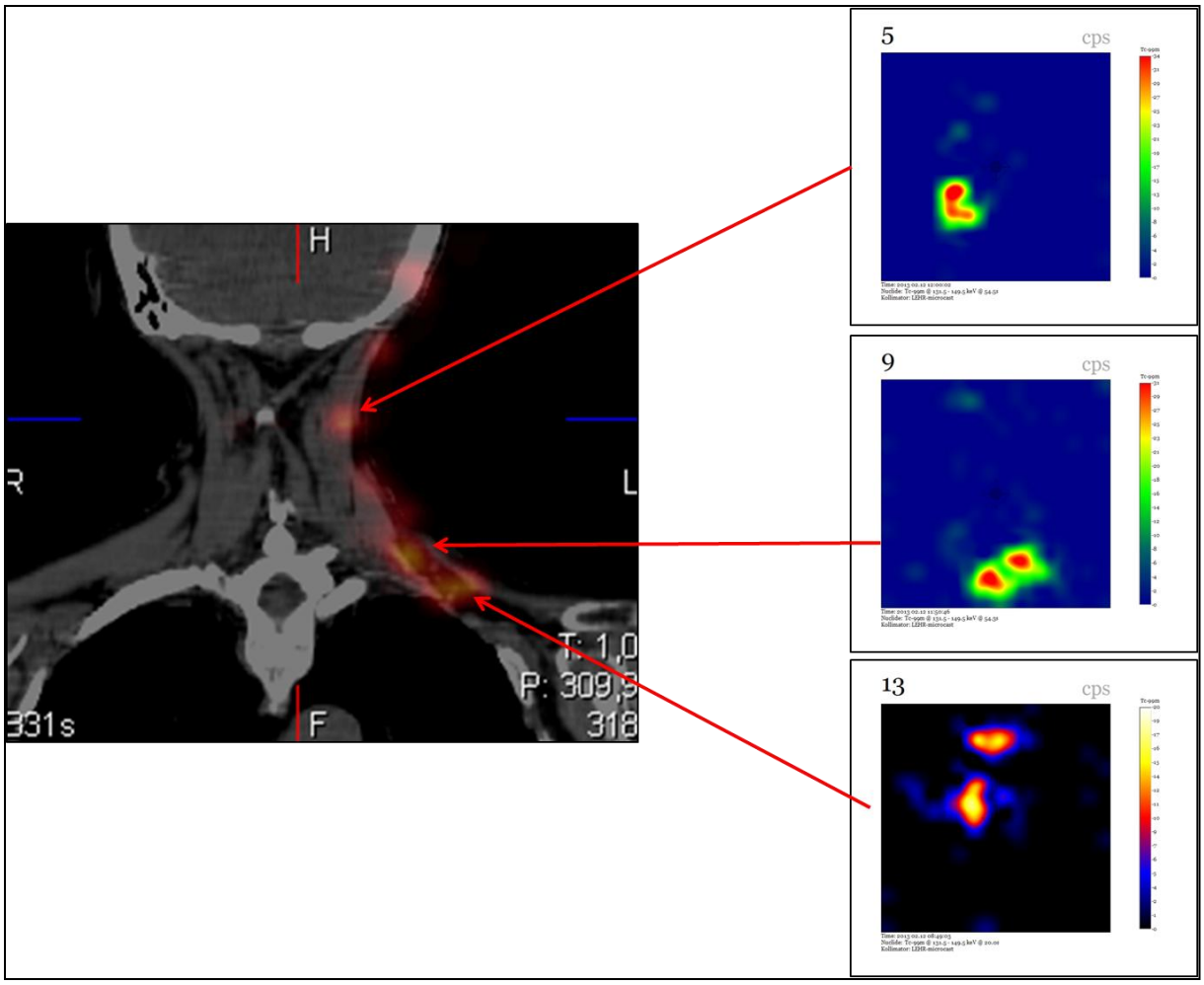

Images courtesy of University Hospital Leipzig, Department of Nuclear Medicine. Director and Chairman: Prof. Dr. Osama Sabri, MD, PhD

Left: SPECT/CT of a person with head and neck cancer. Image acquired with typical SPECT/CT acquisition times (15 – 20 sec. per angular increment).

Right: Images acquired by CrystalCam with high resolution collimator.
Upper image shows 2 lymph nodes acquired intra-operatively with 54 sec. acquisition time.
Middle image shows 2 lymph nodes acquired intra-operatively with 54 sec. acquisition time.
Bottom image shows 2 lymph nodes pre-operatively with 20 sec. acquisition time.

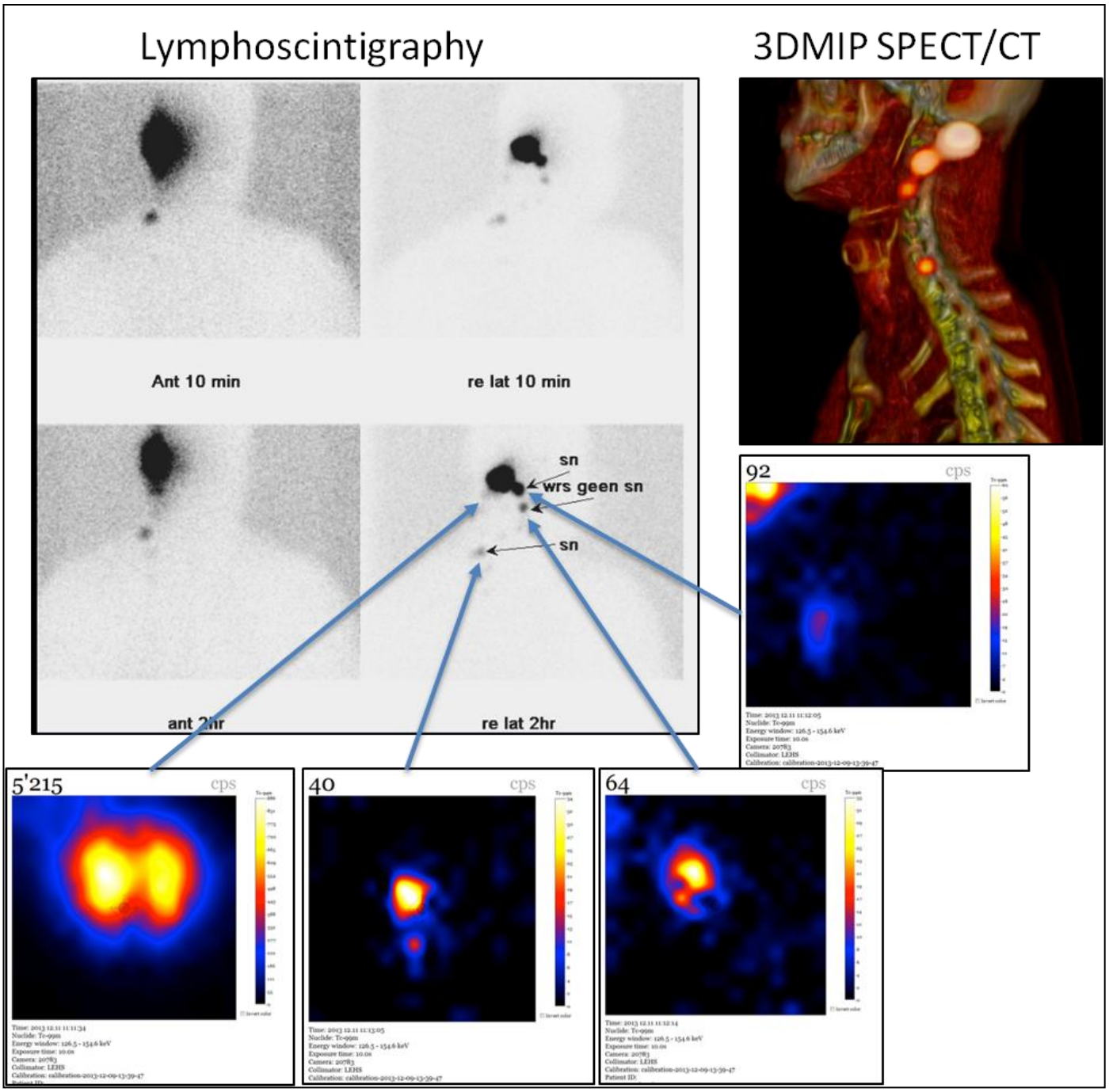

Images courtesy of Bas Pouw, Netherlands Cancer Institue

SPECT/CT of a person with head and neck cancer. Image acquired with typical SPECT/CT acquisition times (15 – 20 sec. per angular increment).

CrystalCam images acquired with high sensitivity collimator and 10 sec. acquisition time

Breast cancer

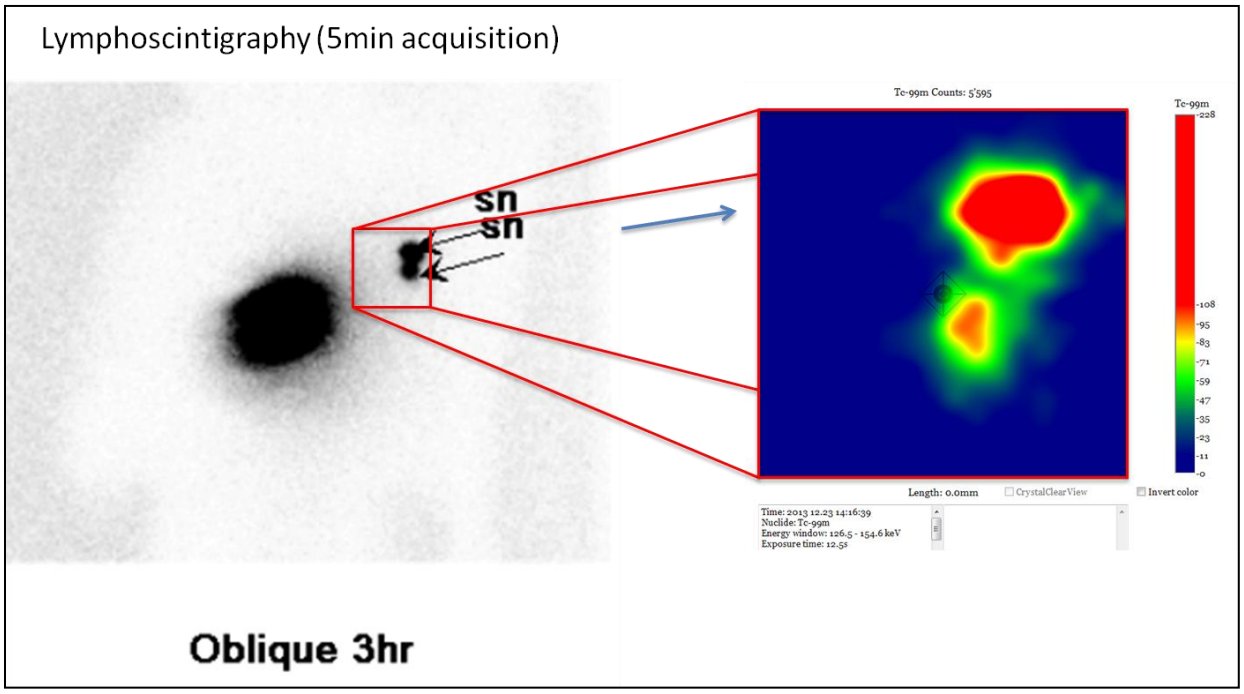

Images courtesy of Bas Pouw, Netherlands Cancer Institue

CrystalCam image with high sensitivity collimator and 12.5 sec. acquisition time

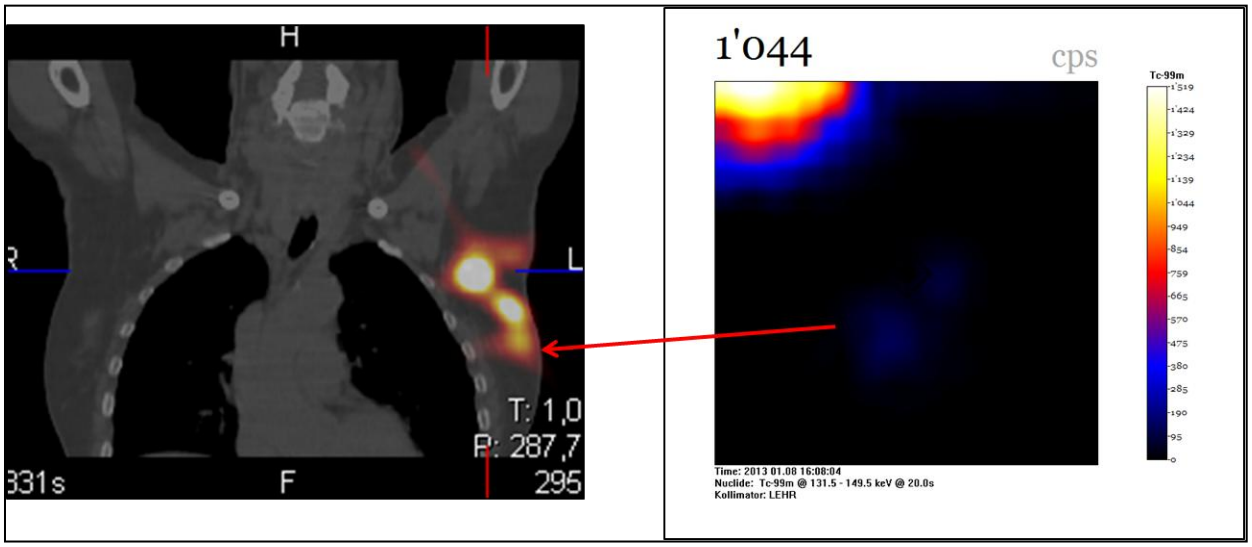

Images courtesy of University Hospital Leipzig, Department of Nuclear Medicine. Director and Chairman: Prof. Dr. Osama Sabri, MD, PhD

Left: SPECT/CT of a woman with breast cancer. Image acquired with typical SPECT/CT acquisition times (15 – 20 sec. per angular increment).

Right: Images acquired by CrystalCam with high resolution collimator.
Upper image shows 2 lymph nodes acquired pre-operatively with 20 sec. acquisition time.

Lymph flow scintigraphy

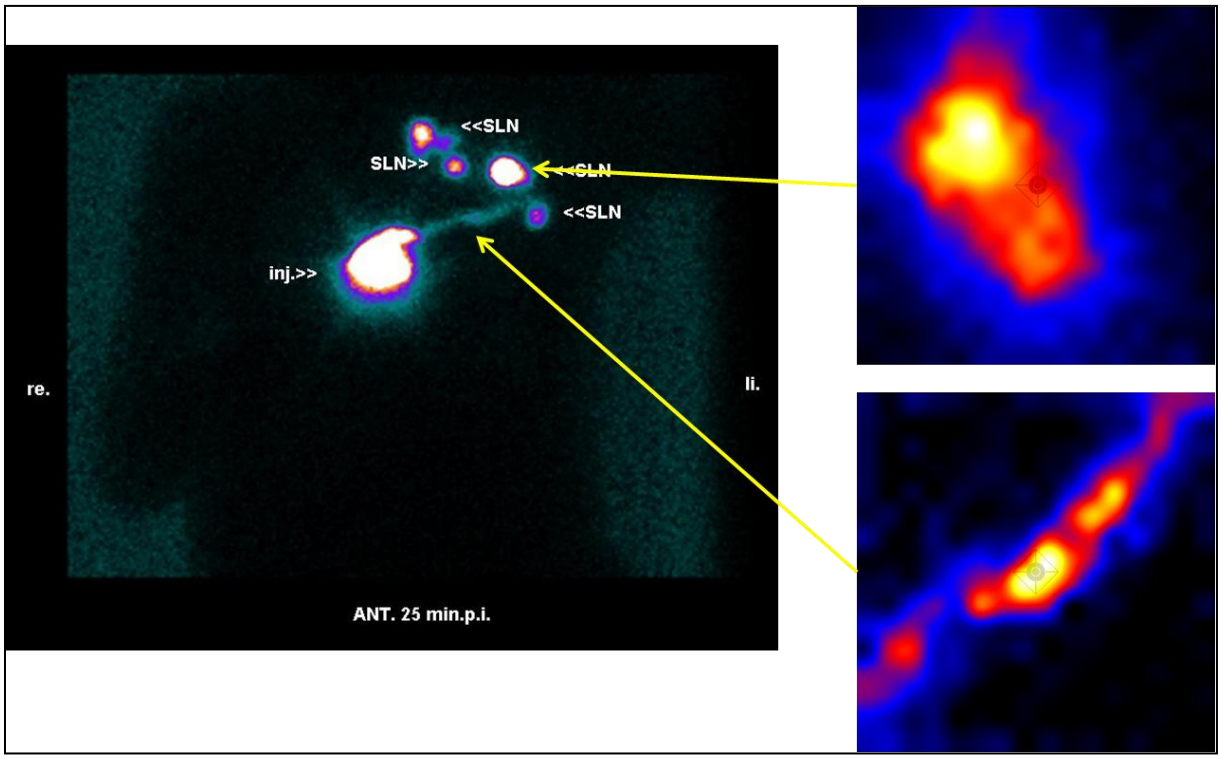

Images courtesy of Dr. Peter Knoll and Dr. Siroos Mirzaei, Wilhelminenspital, Dept. of Nuclear Medicine with PET Center, Vienna, Austria

Small animal research

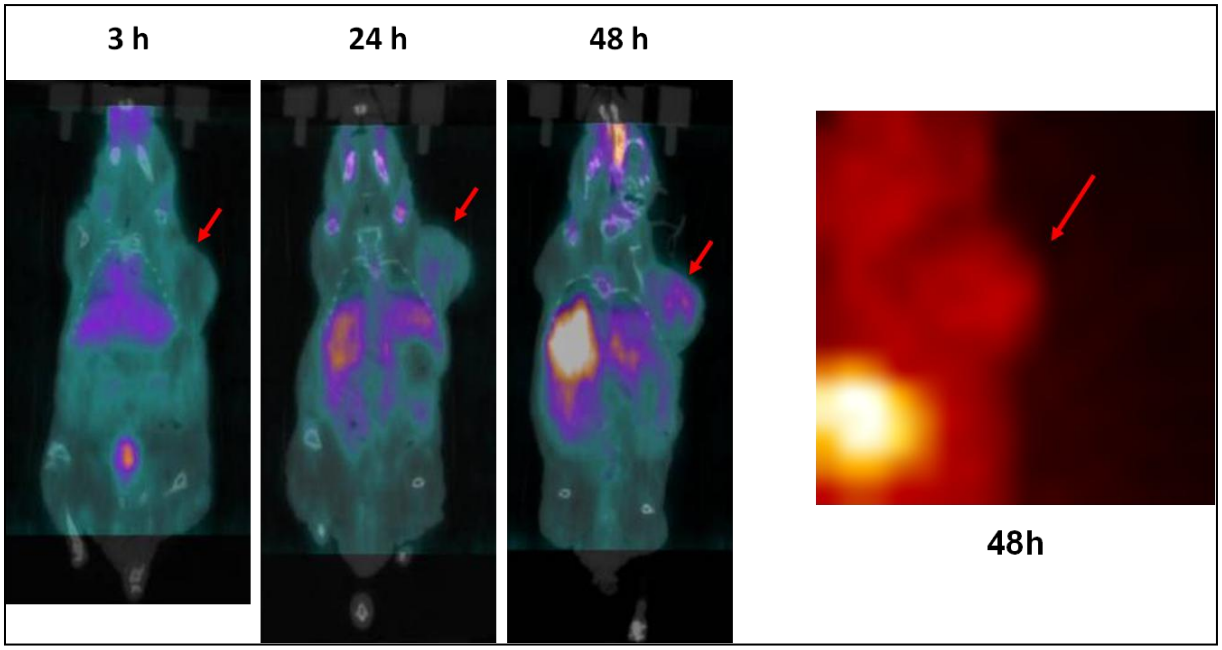

Images courtesy of Dr. Peter Knoll and Dr. Siroos Mirzaei, Wilhelminenspital, Dept. of Nuclear Medicine with PET Center, Vienna, Austria
Gallium 67 scan